



Restoration of proximal caries lesions in the posterior area with tight proximal contacts

By Dr. Radoslav Asparuhov, Bulgaria



Dr. Radoslav Asparuhov graduated with Honours from the Faculty of Dental Medicine of the Medical University in Sofia (Bulgaria) in 1998. He specializes in aesthetic dentistry and dentistry with Minimum Intervention in his own private practice in Sofia that he started in 1999. Since January 2003, he is a consultant for GC Europe NV.

Direct posterior proximal restorations can be a real challenge for the dentist. With easy handling, good aesthetic properties and the proper operative techniques, it is possible to retrieve predictable and excellent results with posterior composites.

Case report

A 38-year-old female patient consulted the dental office because of food impaction and moderate pain when

eating sweet or sour food. Upon clinical and radiographical examination, secondary caries was found on the proximal areas of tooth #16 (Fig. 1).

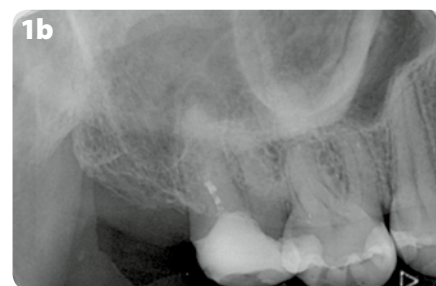
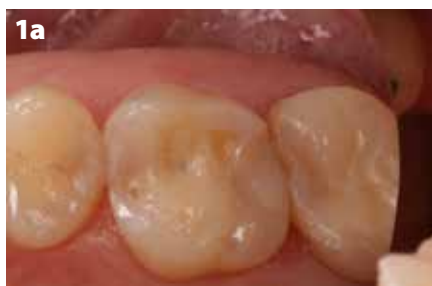

Figure 1: Initial situation. **a)** Intraoral view, showing an MOD restoration with discoloured margins on tooth #16; **b)** Radiograph of the initial situation revealing secondary caries on tooth #16.



CONTINUE READING ON...

LESEN SIE WEITER...

CONTINÚE LEYENDO EN...

CONTINUER LA LECTURE SUR ...

CONTINUA A LEGGERE...

GC

GET CONNECTED

SMILE
PROGRAM

